

Position Responsible: Medical Director  
CGC reviewed: August 2017

Issue Date: June 2018  
Review Date: June 2020

---

|                    |   |
|--------------------|---|
| Related Documents: | <p>PAM Resuscitative Thoracotomy<br/>TEMPO, EoE Trauma Network<br/>Thirteen survivors of prehospital thoracotomy for penetrating trauma; a prehospital physician-performed resuscitation procedure that can yield good results. Davies GE, Lockey DJ. J Trauma 2011 May; 70(5):E75-8</p> <p>Pre-hospital thoracotomy: a radical resuscitation intervention come of age? Lockey DJ, Davies G. Resuscitation. 2007 Dec; 75(3):394-5</p> <p>Emergency thoracotomy: "How to do it". Wise D, Davies G, Coats T, Lockey D, Hyde A, Good A. Emerg Med J. 2005 Jan;22(1):22-4</p> |
|--------------------|---|

---

*This document is the intellectual property of Magpas*

---

## 1.0 Aim

- To ensure that all medical staff are familiar with the indications, process and procedure for delivering resuscitative thoracotomy in the pre-hospital setting.
- Define the patient population the process aims to save.
- Describe indications for resuscitative thoracotomy.
- Describe the operative process.

## 2.0 Background

- 2.1 Patients who lose their vital signs on scene through penetrating trauma have a poor prognosis. Transportation to hospital, while administering cardiopulmonary resuscitation is pointless; blood flow through the heart is either obstructed or the heart is simply empty through hypovolaemia.
- 2.2 To maximise the chance of survival, surgical intervention should be immediate (within 10mins of loss of vital signs). Pre-hospital resuscitative thoracotomy (PRT) for penetrating chest injury, primarily aims to address one specific group of patients, those with a *simple cardiac wound* leading to *tamponade* and cardiac arrest. It does not aim to address more complicated wounds that have produced hypovolaemic arrest. As the majority of tamponades are clotted, pericardiocentesis is not indicated, formal thoracotomy and pericardotomy is essential. Patients will also require 'quality massage' to ensure return of spontaneous cardiac activity.
- 2.3 In the 'peri-arrest' patient, the decision on whether or not to perform a pre-hospital thoracotomy vs rapid transfer to hospital will depend largely on the distribution of wounds and what the clinician 'expects to find' (i.e. a readily treatable disease such as tamponade vs an aortic injury or high energy lung laceration from gun shot wound). If the transfer time to the nearest Trauma Unit is likely to be less than 15mins, consider performing interventions in the Trauma Unit.

### 3.0 Procedure

#### 3.1 Indications

Penetrating injury likely to result in direct cardiac damage resulting in cardiac arrest or a peri-arrest state.

#### 3.2 Process

- Once there is an indication, the decision to undertake a thoracotomy should be made within 10–15 seconds. This is a clinical diagnosis and should not require monitoring.
- The patient should be rapidly moved to an area where there is 360 degrees of access to perform the procedure.
- Sterile gloves must be worn. Eye protection and head torches should be considered.
- The primary focus of the medical team is to perform the rapid PRT. Other resources can be used to perform intubation or IV access simultaneously.
- Identify the markings for the 4<sup>th</sup> intercostal space. The fourth intercostal space at the mid-axillary line lies approximately level with the nipple in men and the infra-mammary fold in women
- Undertake bilateral simple thoracostomies
- Mark the trajectory of the 4<sup>th</sup> interspace in your mind in a swallow type shape. This will be the line of the skin incision.
- Make a broad skin incision along the line of the 4<sup>th</sup> interspace that joins both thoracostomy wounds. The incision should take the shape of swallow and should aim to get through all skin layers to fat / chest wall.
- Using a pair of Tuffcut Shears extend the thoracotomy wounds on both sides up to the breastbone. Again in the line of the 4<sup>th</sup> space. It may be possible to cut through the breastbone with the shears. If not, the sternum could now be breached with a Gigli saw if available. Pass the Spencer Wells behind the sternum grab the Gigli wire and pull it behind the sternum. Attach the wire to Gigli handles and saw. It should take little more than 2 or 3 pulls.
- Before opening the chest up extend the incision in the intercostal space posteriorly to the posterior axillary line. This will allow you to open the chest fully in a “clamshell” fashion, maximising the exposure and aiding identification of anatomy.
- Lift the chest open wide. Use suction if necessary to help clear the field and help identify anatomy.
- Identify the heart; if tamponade is present the pericardium may look tense. The pericardium must be opened even if there is no tamponade in order to inspect the heart. Using the Spencer Wells to raise a “tent” of pericardium on the anterior surface of the heart. Cut a small vertical hole. Extend the hole vertically with scissors; try not to tear it.
- Remove any blood clots with your hands. The heart may fibrillate or beat spontaneously as this happens.
- If the heart makes no spontaneous movement, try flicking it with your finger. If no movement comes about, begin massage. Focus on the quality of massage you are providing. Consider getting an assistant to compress the descending aorta on the spinal

column. Use a two handed technique and ensure the heart is flat in its bed and not kinked on its vascular pedicle

- By this time IV access should have been established. Load the heart with volume - you will feel whether it is empty or not.
- If myocardial activity is sluggish despite adequate filling then 1 mg of intracardiac adrenaline should be delivered to the right ventricle.
- Massage should be continued until myocardial activity is good.
- If the procedure is successful the internal mammary arteries may now bleed and require ligation.
- Spontaneous ventilation may occur even on scene depending on the degree of cerebral hypoxia.
- Anaesthetise the patient as required.

### 3.3 Cardiac wounds

- Cardiac wounds should be controlled with direct finger pressure or sutured if required. Consideration can also be given to using a small Foley catheter.
- Wounds adjacent to coronary arteries should be treated with caution when suturing.

### 3.4 Aortic occlusion

- If it appears that exsanguination is the cause of cardiac arrest then this should be one of your first, and most important tasks. You may need to begin this yourself and then carefully handover to another suitable clinician. Using the left hand enter the left hemithorax and pass it up behind the lung until the spine is felt. Using the fingers of the left hand compress any soft tissue structures in front of the spine onto the spine's anterior surface. You should feel a pulse from a spontaneous or augmented cardiac compression if the heart is adequately full.

## 4.0 Triage and disposition

4.1 All patients who have undergone successful active resuscitation should be triaged using the triage tool. Pre-alert the hospital requesting cardiothoracic support and massive blood loss protocol.

4.2 If despite maximal resuscitation the situation appears hopeless, then life may be pronounced extinct at the scene.

4.3 All cases successful or un-successful must be discussed with the duty on-call Consultant after the procedure is performed. There is no requirement to call before.

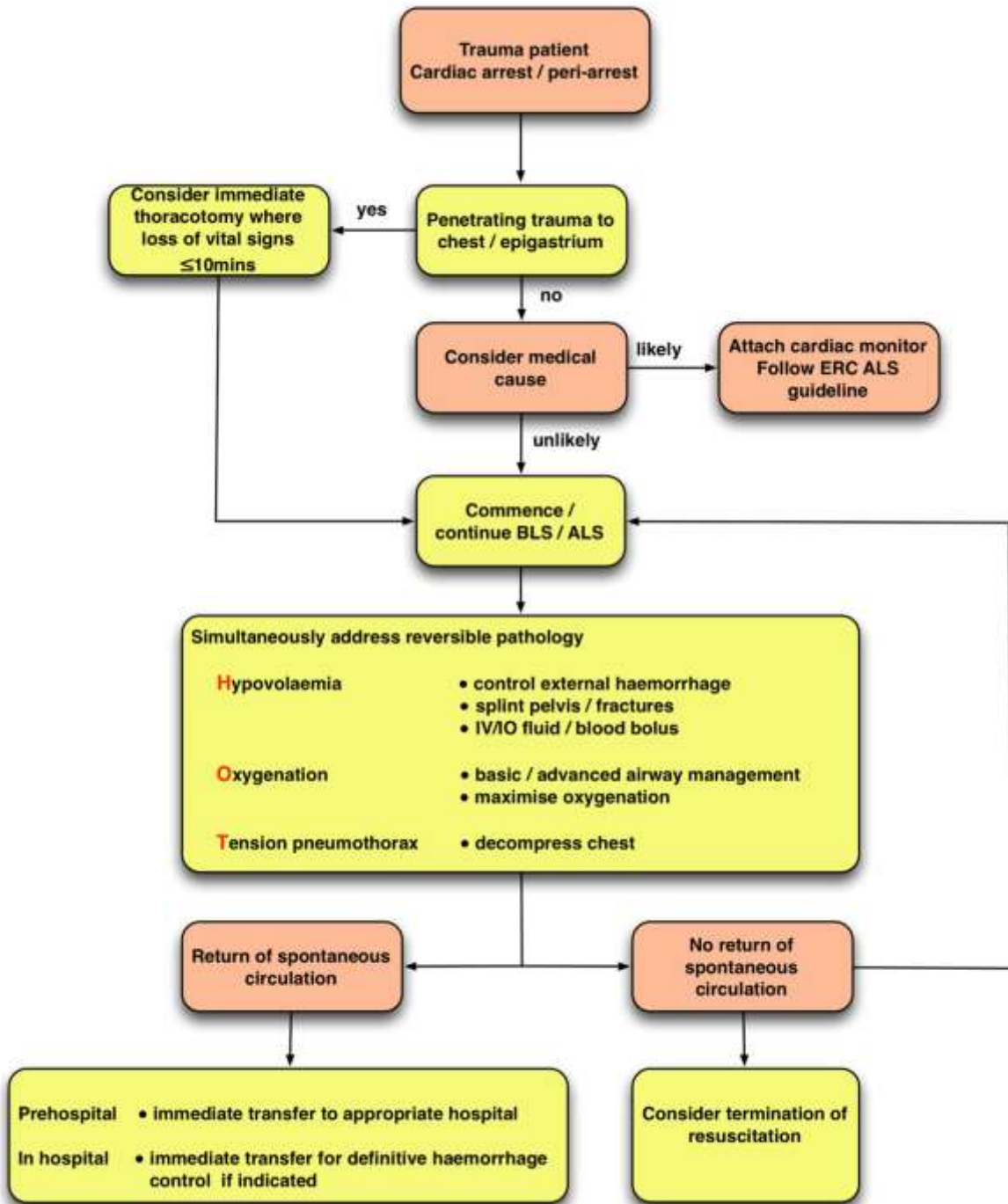
## 5.0 Documentation and audit

5.1 Clear documentation of the procedure should be included in the patient care record and associated database.

5.2 Cases will be debriefed and audited as soon as possible after the intervention. Learning will be shared with all partners.

# Appendix 1

## Traumatic cardiac arrest treatment algorithm



BLS: basic life support, ALS: advanced life support, ERC: European Resuscitation Council, IV: intravenous, IO: intraosseous